

## Upper Extremity Injuries: The Common and Commonly Missed

Arun Sayal, MD  
Emergency Physician,  
University of Toronto



1

### This session will be recorded

- We are recording this Zoom session so that it can be watched again at your convenience, and so that we can share it with your colleagues who were not able to join us today.
- If you would prefer that this recording **not** be shared with your EM colleagues, please email [amcknight@ghem.ca](mailto:amcknight@ghem.ca) within 24 hours of the session.
- We will share the presentation slides and other materials (journal articles, etc.) by email; you will have access to all materials regardless of whether the recording is shared.



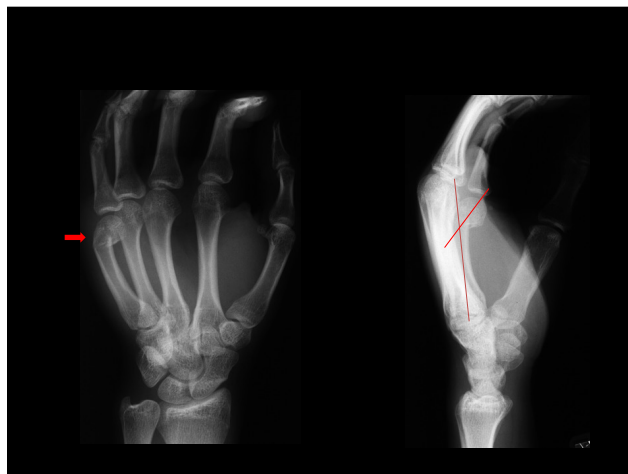
2

### Please also note:

- The information in this presentation and the video recording is up to date as of the date it was recorded Nov 26, 2020.
- It has not been updated to include any subsequent advances in practice, and the information presented in this video does not replace hospital, health centre, or governmental guidelines.



3

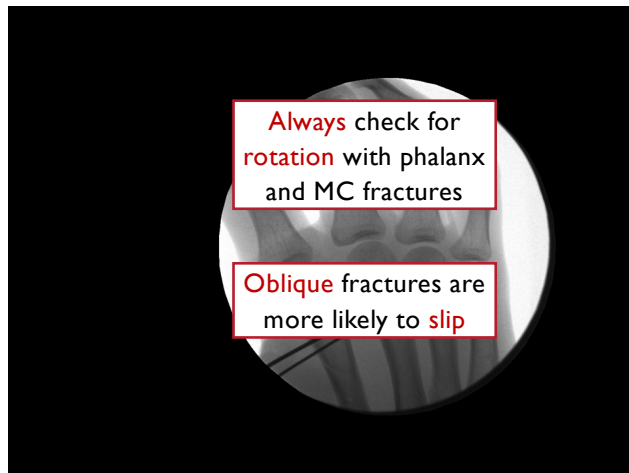


4

### 'TRAMP'

- T** – Traction
- R** – Reduction
- A** – Apply splint materials
- M** – Mold
- P** – Position

5



6

### Common

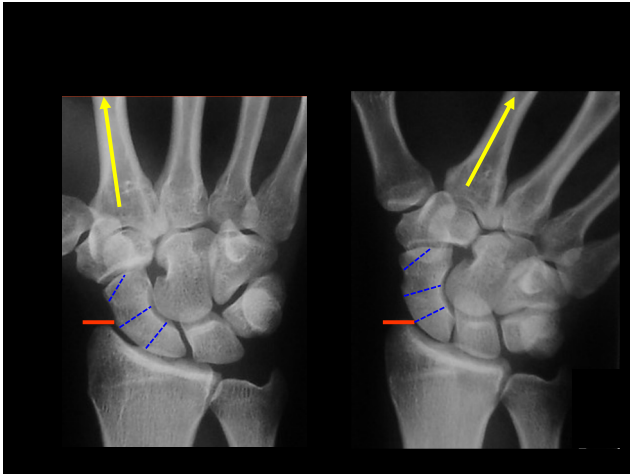
- Stable Dorsal** Disloc'n
- Boxer's** Fracture

7

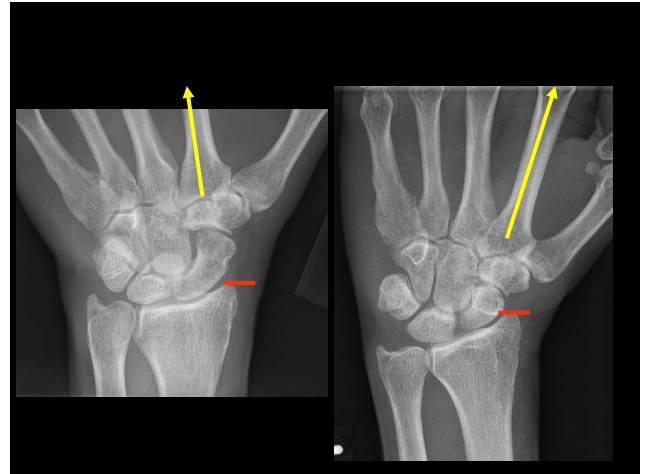
### Commonly Missed / Mismanaged

- Unstable** Dorsal Disloc'n
- Volar** PIP Disloc'n
- MC **Shaft** Fracture
- Rotation

8



9



10

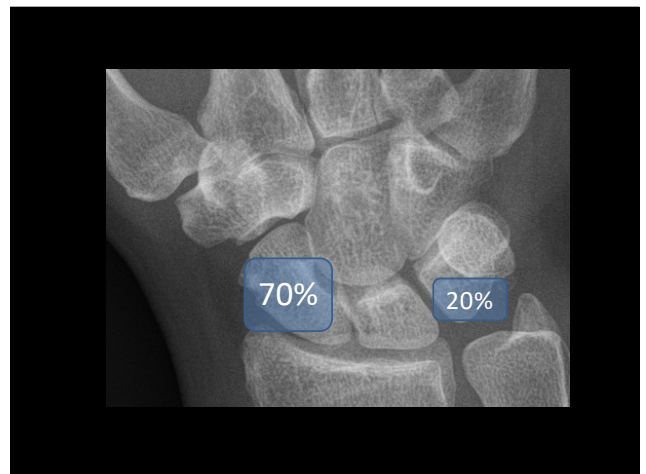
For snuffbox tenderness, ulnarly deviate the wrist

Scaphoid fractures are uncommon <15 and >50

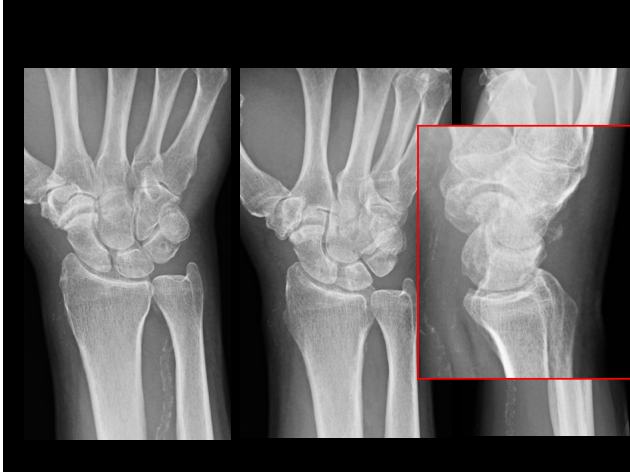X-rays are good - not perfect

Extra views


11



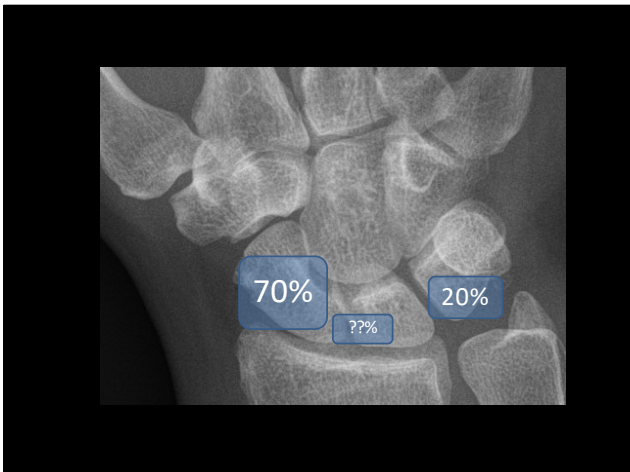
12



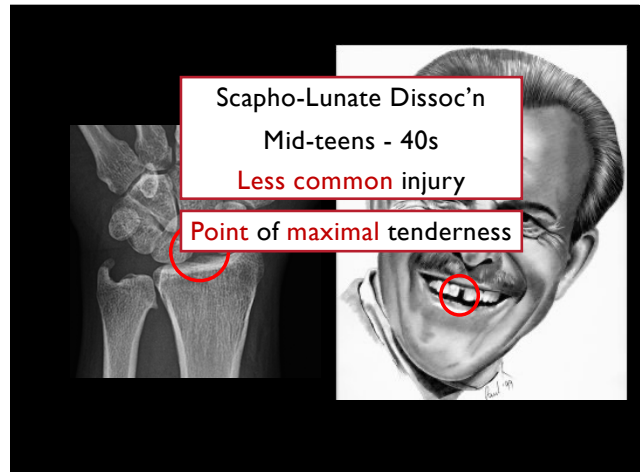
13



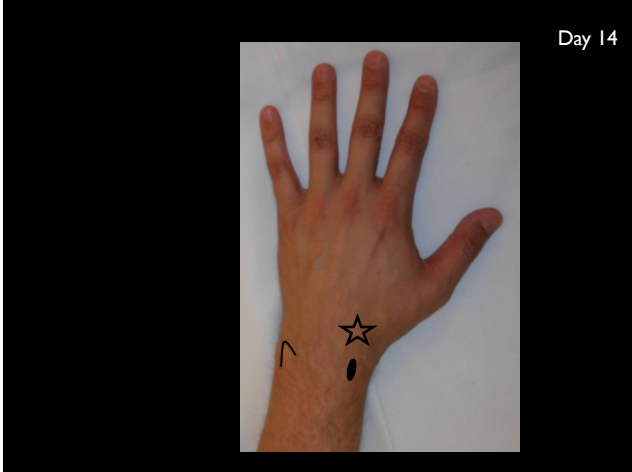14



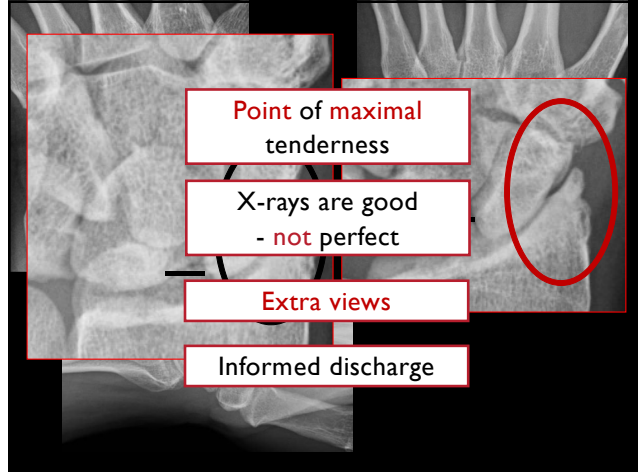
15



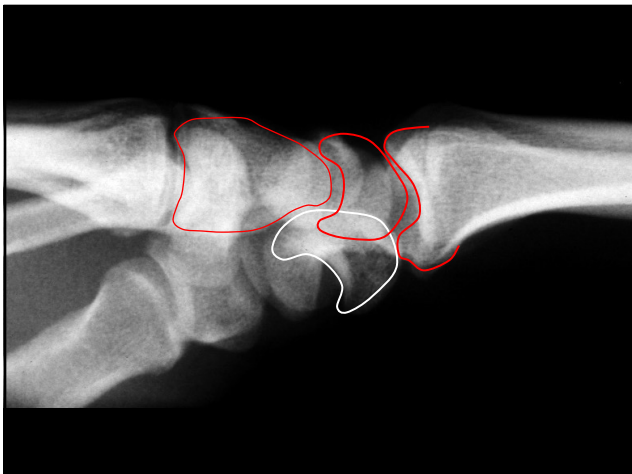
16



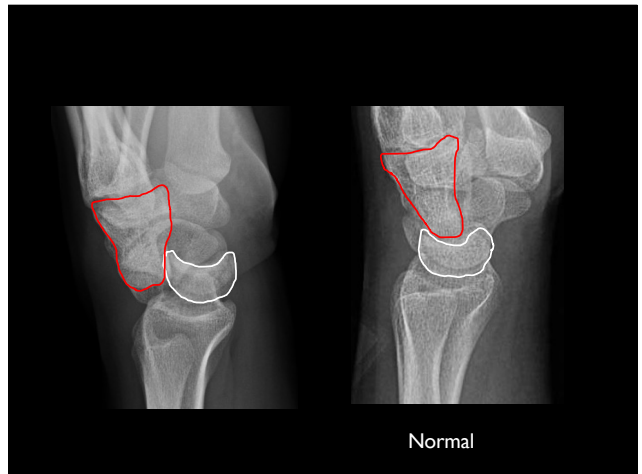
17



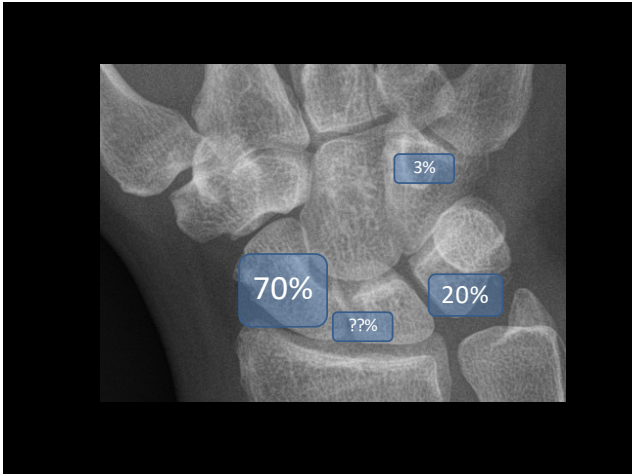
18



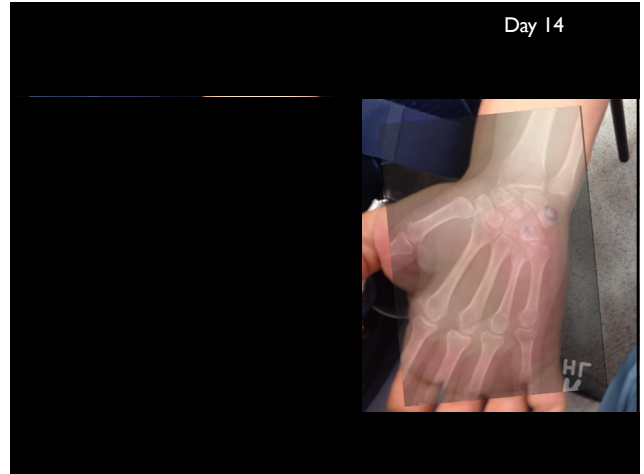
19



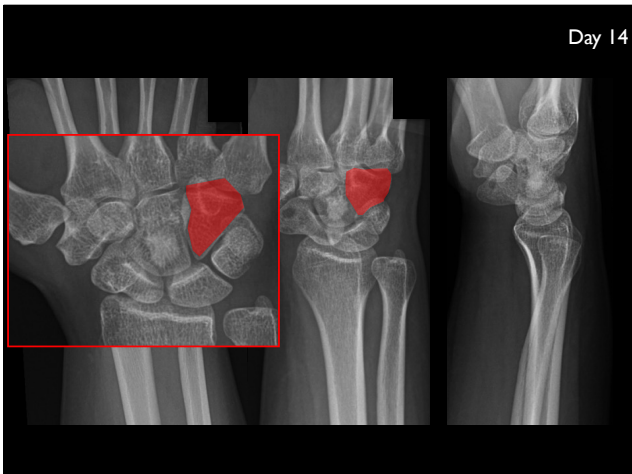
20



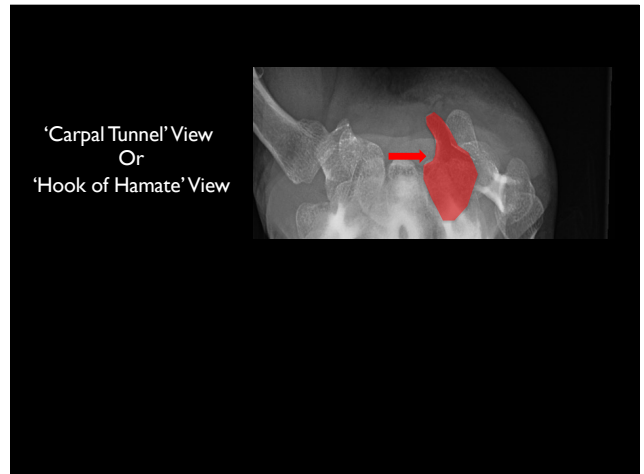
21



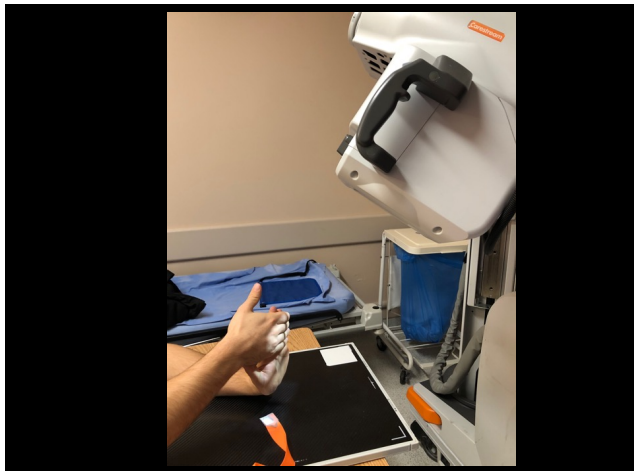
22



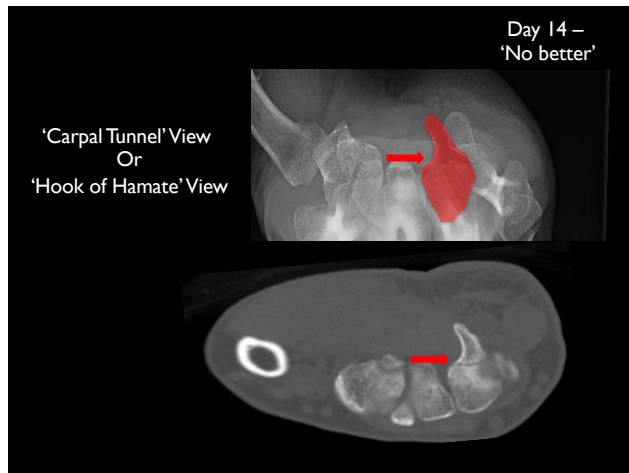
23



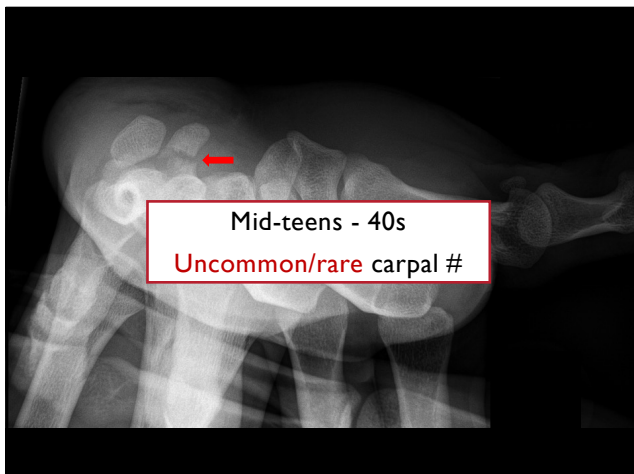
24



25



26



27

Commonly Missed  
/ Mismanaged

3 tests for scaphoid  
Rest of carpals

28

---

**Upper Extremity Injuries:**  
The Common and  
Commonly Missed

Arun Sayal, MD  
Emergency Physician,  
University of Toronto

